

Use of PVA impregnated with Methylene Blue and Gentian Violet Dressing on a multi-site back abscess of an immigrant just arriving to the United States

By: Mary Webb, RN, BSN, MA CIC, Infection Control Practitioner, San Mateo Medical Center, County of San Mateo, San Mateo, California

Clinical Problem

Family members brought 53 year-old female patient to hospital emergency department for redness and pain on left upper back of one week duration with nausea, vomiting and increased lethargy. History was of poorly controlled diabetes, hypertension, obesity, and chronic renal failure.

Management

After receiving surgical debridement in the ER, she was admitted for IV antibiotics and wound care. Patient continued to experience pain and redness, persistent fever and lethargy with worsening leukocytosis. Second surgical debridement revealed pus pockets surrounding the wound. Cultures grew Methicillin-sensitive staphylococcal aureus and staphylococcus aureus bacteremia. Based upon the painful nature the wound and wound culture results, the team selected PVA impregnated with Methylene Blue and Gentian Violet followed by secondary dressing. This absorbed exudate and continued debriding of the wound.

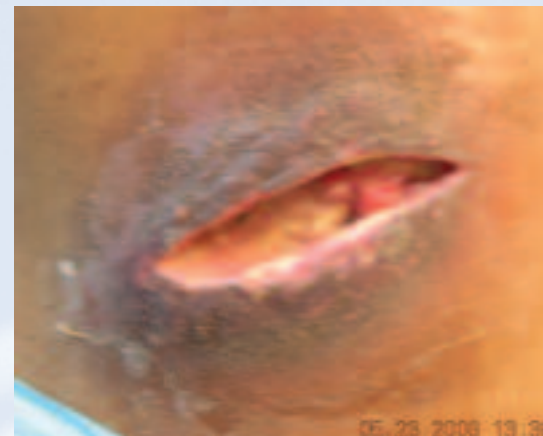Patient Outcome

In 24 days wound was clean and granulating with a moist wound environment. Patient was discharged home with patient and family teaching for continued wound care.

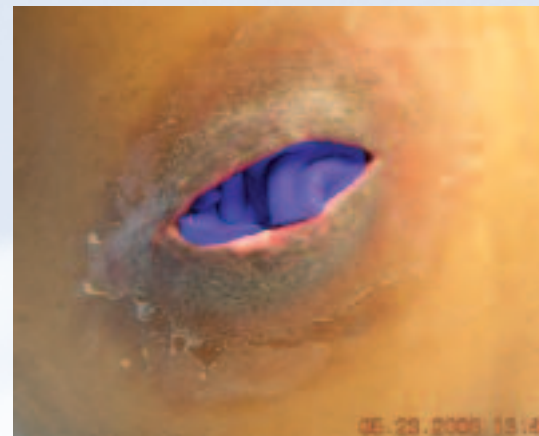
Conclusion

Despite co-morbidities, wound care team was able to effectively manage deep abscess on patient left upper back, decrease pain and tenderness during dressing changes and improve patient comfort between dressing changes.

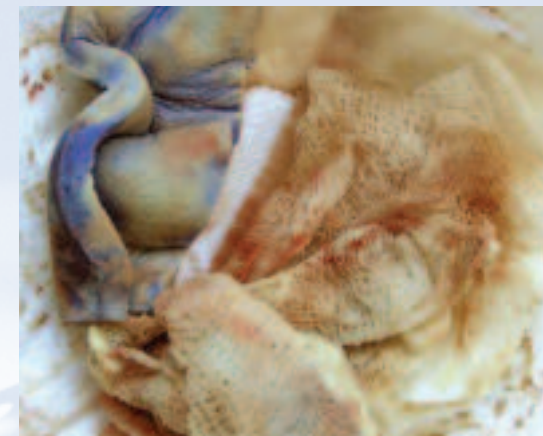
Sponsored by: **Hydrofera**[®]
Pioneering Advancements in PVA Technology



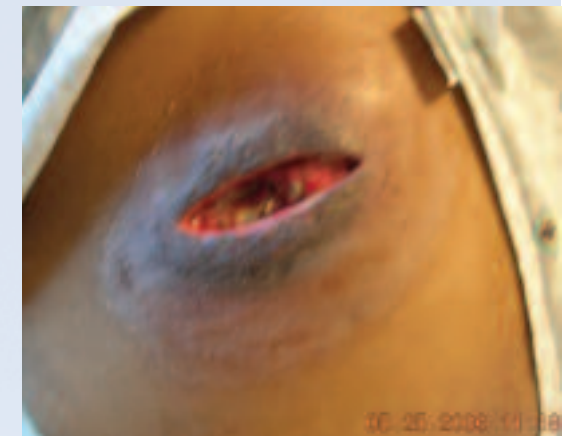5-23-2006
Wound prior to treatment.



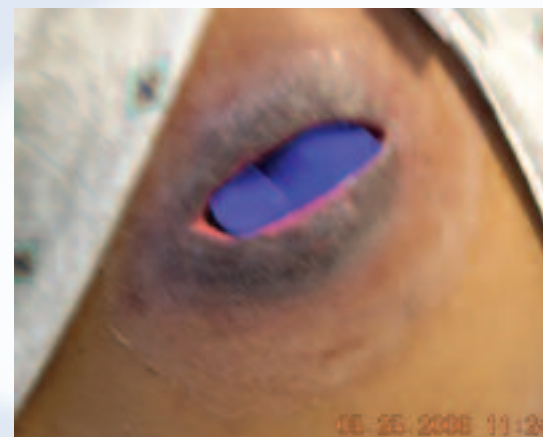5-23-2006
Hydrofera Blue inserted into wound.



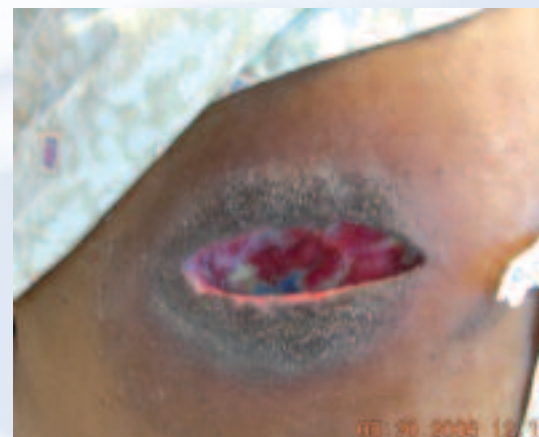5-25-2006
Hydrofera Blue (turning white) and secondary dressings after 2 days treatment.



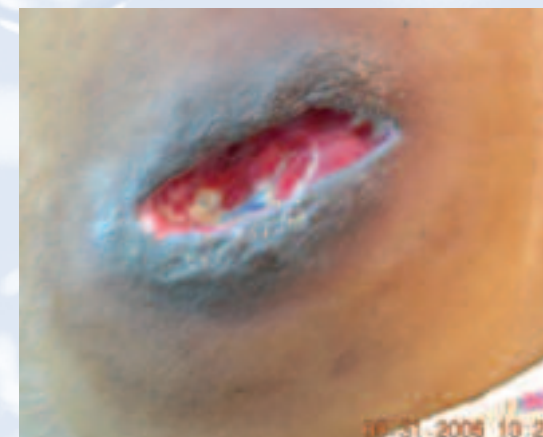5-25-2006
Wound after 2 days of treatment.



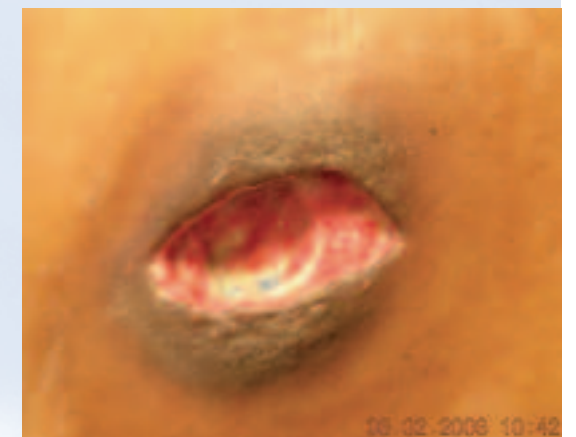5-25-2006
Hydrofera Blue inserted into wound.



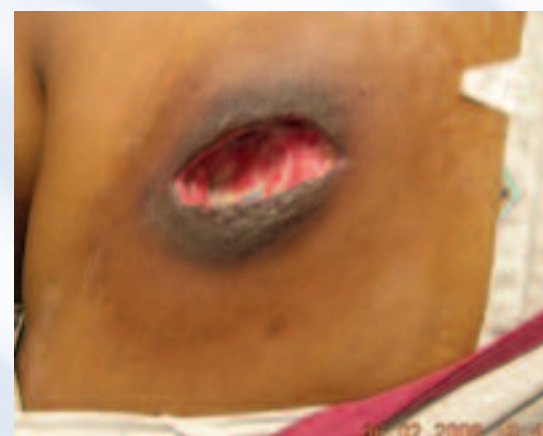5-30-2006
Wound after 7 days of treatment.



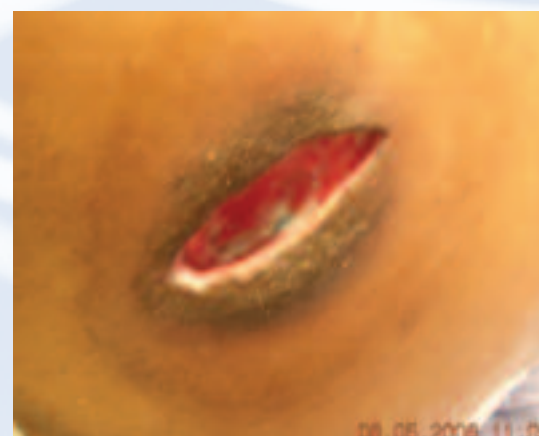5-31-2006
Wound after 8 days of treatment.



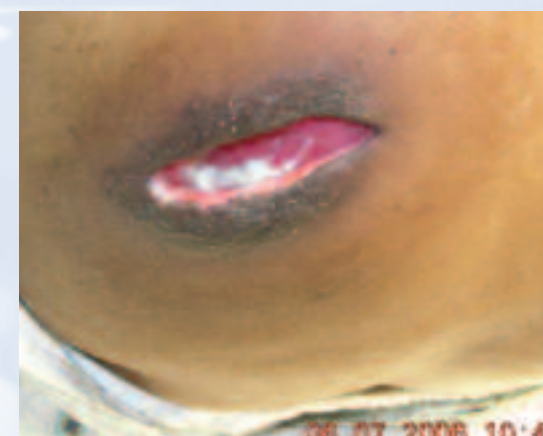6-02-2006
Wound after 10 days of treatment.



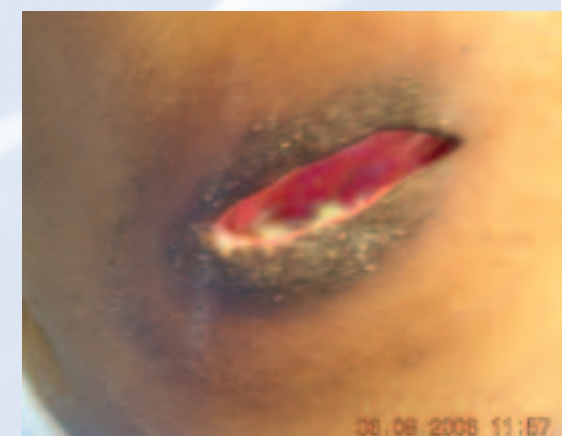6-02-2006
Wound after 10 days of treatment.



6-05-2006
Wound after 13 days of treatment.



6-07-2006
Wound after 15 days of treatment.



6-08-2006
Wound after 16 days of treatment.