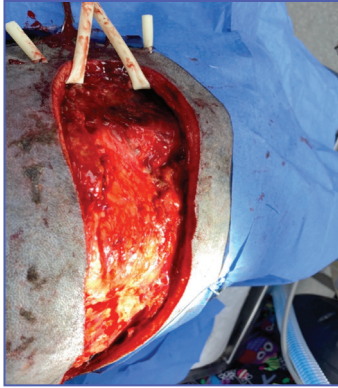
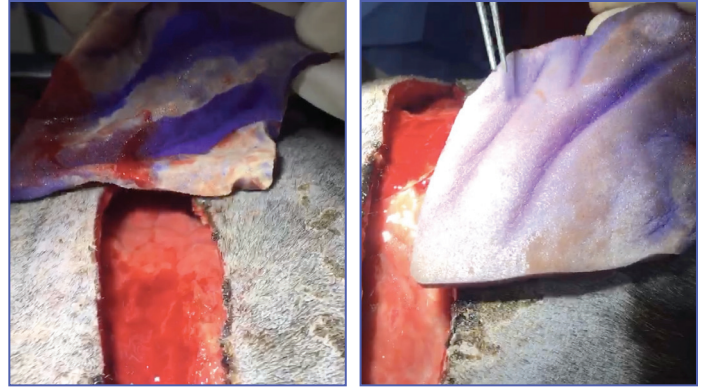


Patient: 7-year-old boxer presents with abscessed wound on back resulting from a dog bite. Tissue was necrotic and dog was refusing to eat, drink, or walk

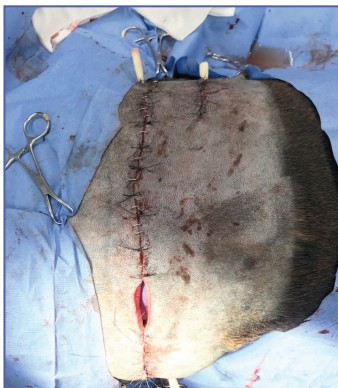Wound Treatment:



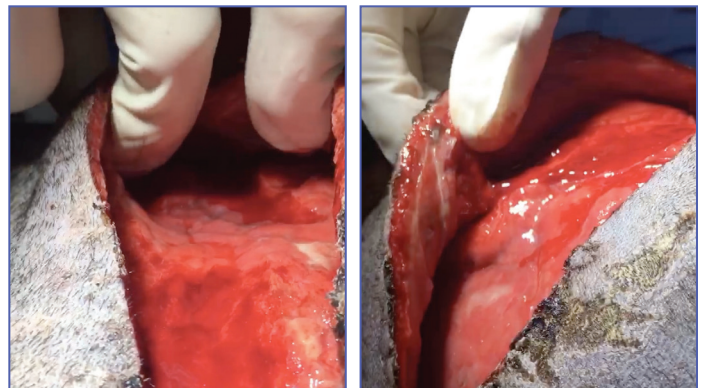
12/19
Post-surgical debridement, prior to VetBlue PVA being used. Clear evidence of necrotic tissue.



12/24
Sutures were removed and dressings were extracted. Dressing had changed color from blue to white, indicating uptake of heavy bioburden.



12/19
VetBlue PVA placed in wound and wound was sutured, with small window for monitoring the color of the dressing.



12/24
The Result: a clean wound cavity with granulating tissue.

Case provided by:
Dr. Jeffrey Logan, DVM
Northern Rhode Island Animal Hospital



For product questions and samples please call
Customer Service at 1-860-337-7730.

Hydrofera Dressings manufactured by:
Hydrofera, LLC, 340 Progress Drive
Manchester, CT 06042, USA
www.hydrofera.com

VetBlue and the VetBlue logo are trademarks of Hydrofera, LLC. ©2021
056-0321
MADE IN USA

Hydrofera[®]