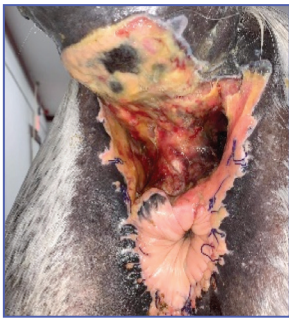



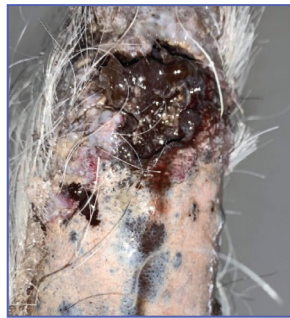Patient: 17-year-old thoroughbred mare
History: Previous melanoma surgery in 2016.
Recurrence of melanoma in January 2020.
Melanoma Surgery-January 14, 2020.
Tail begins to necrose: January 16, 2020.

Wound Treatment:

Initial Treatment Regimen: Chlorhexidine Spray



1/14
Excision of melanoma

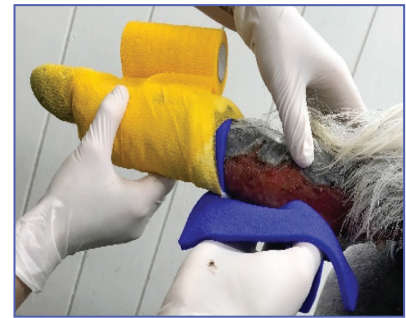


1/16
Necrosis at mid-tail



2/21
Tail fully necrosed and infected

VetBlue PVA Dressing Applied

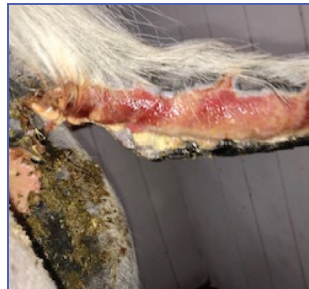

2/21

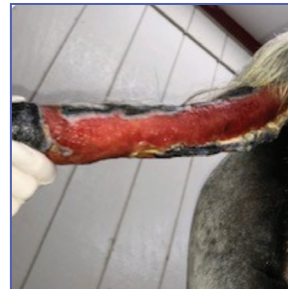First Dressing Change (turns white after being in contact with bacteria)



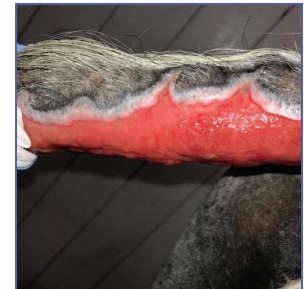2/22



Continued Application of VetBlue™ Antibacterial Foam Dressing

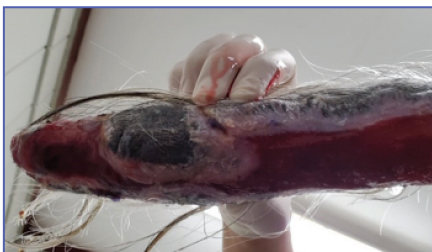

2/26

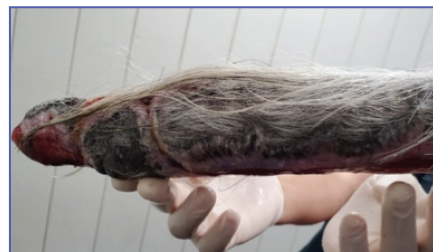

3/4

VetBlue PVA Antibacteria Foam Dressing Promotes Autolytic Debridement Essential To The Continued Wound Healing Process



3/29



7/22
Healed

Case provided by:
The Myhre Equine Clinic
Dr. Grant D. Myhre, DVM and Dr. Amr Alsherif, DVM



For product questions and samples please call
Customer Service at 1-860-337-7730.

Hydrofera Dressings manufactured by:
Hydrofera, LLC, 340 Progress Drive
Manchester, CT 06042, USA
www.hydrofera.com

VetBlue and the VetBlue logo are trademarks of Hydrofera, LLC. ©2021
091-0421
MADE IN USA

Hydrofera®