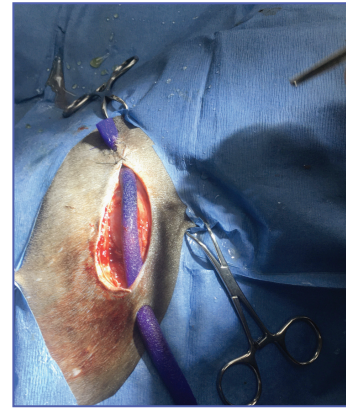
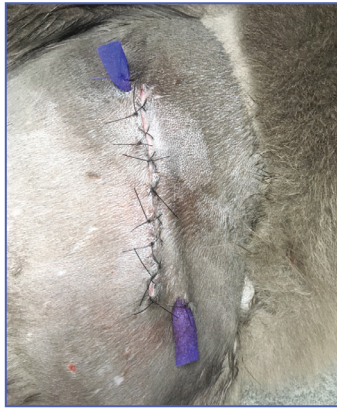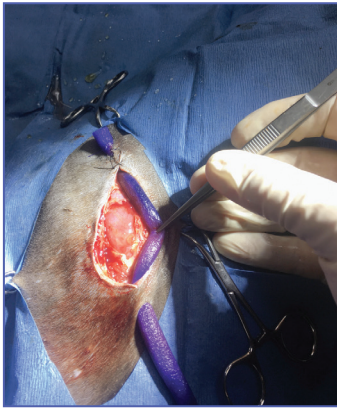


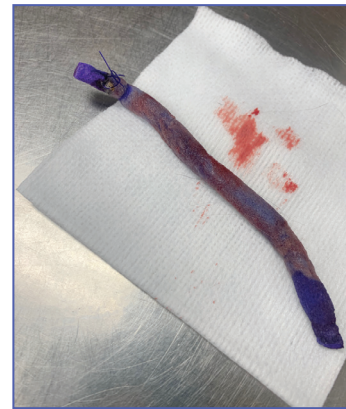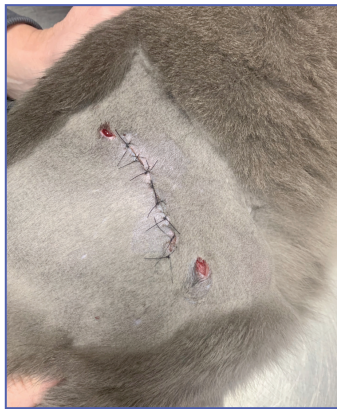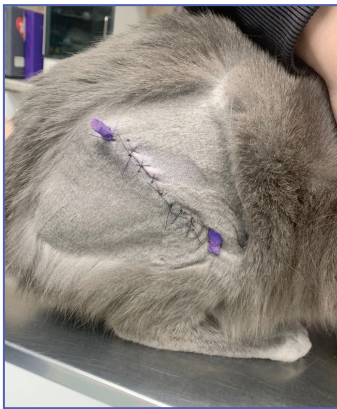Patient: Male cat presented with abscessed bite wound after having been attacked by a coyote.

Wound Treatment:



2/7

A VetBlue PVA Tunnel dressing was used in place of a Penrose drain. The tunnel dressing was sutured in place, leaving ends exposed to allow drainage. This also allowed the owner to monitor the color and hydration of the dressing.



2/10

The VetBlue PVA Tunneling dressing was easily extracted with the sutures in place. Dressing had changed in color from blue to white indicating heavy bioburden. Wound went on to heal with no recurrence of an abscess.

Case provided by:
Dr. Jeffrey Logan, DVM
Northern Rhode Island Animal Hospital



For product questions and samples please call
Customer Service at 1-860-337-7730.

Hydrofera Dressings manufactured by:
Hydrofera, LLC, 340 Progress Drive
Manchester, CT 06042, USA
www.hydrofera.com

VetBlue and the VetBlue logo are trademarks of Hydrofera, LLC. ©2021
057-0321
MADE IN USA

Hydrofera®