

# A Reprint from Surgical Technology International XXVI

## GENTIAN VIOLET AND METHYLENE BLUE POLYVINYL ALCOHOL FOAM ANTIBACTERIAL DRESSING AS A VIABLE FORM OF AUTOLYTIC DEBRIDEMENT IN THE WOUND BED

ANDREW JOSEPH APPLEWHITE, MD  
PHYSICIAN  
BAYLOR WOUND CENTER, DALLAS, TEXAS

BROCK LIDEN, DPM  
STAFF, CIRCLEVILLE FOOT & ANKLE CENTER  
REYNOLDSBURG PODIATRY CENTER, REYNOLDSBURG, OHIO

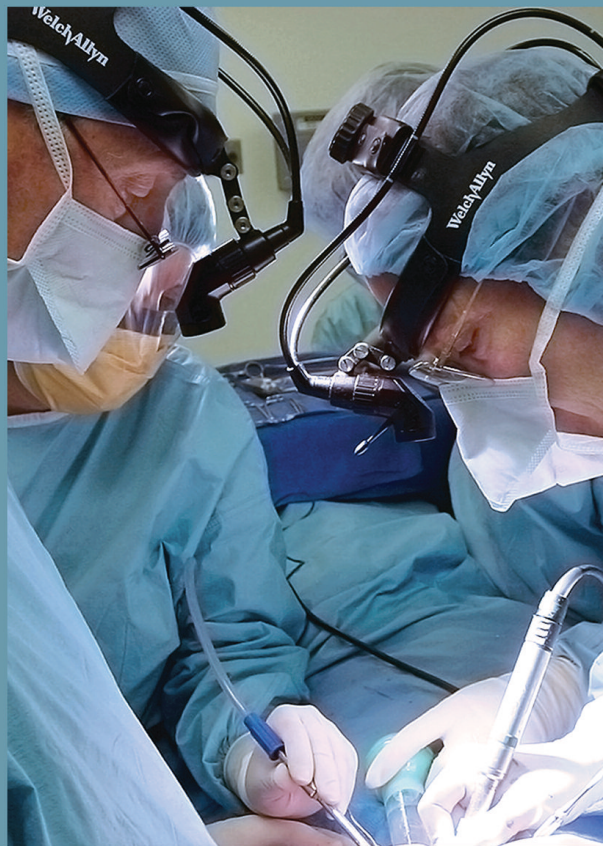PAUL ATTAR, PhD, MBA  
PRESIDENT  
BRIDGE PTS, SAN ANTONIO, TEXAS

QUYEN STEVENSON, ARNP, CWOCN  
WOUND AND OSTOMY NURSE PRACTITIONER  
VETERANS AFFAIRS PUGET SOUND HEALTHCARE SYSTEM  
SEATTLE, WASHINGTON

### SURGICAL TECHNOLOGY

INTERNATIONAL XXVI

International  
Developments  
in Surgery and  
Surgical  
Research



Edited by:

Zoltán Szabó, PhD, FICS, Harry Reich, MD, FACOG, Manabu Yamamoto, MD, PhD  
Harold Brem, MD, FACS, Steven F. Harwin, MD, FACS  
Michael T. Manley, PhD, FRSA, Michael A. Mont, MD

# Choose Blue.

## Hydrofera Blue Classic dressings



To overcome key barriers to healing, choose Hydrofera Blue Classic dressings for:

Broad-spectrum  
antibacterial  
protection

Rapid wicking  
and exudate  
retention

Autolytic  
debridement

Edge effect

Learn more. Contact Hollister at **1-888-740-8999** or visit [www.hollisterwoundcare.com](http://www.hollisterwoundcare.com).

Choose a better path for wound bed preparation. **Choose Blue.**

Hydrofera**BLUE**

 Hollister

Hydrofera Blue Classic dressings also marketed as Hydrofera Blue dressings.

The Hollister logo is a trademark of Hollister Incorporated. Hydrofera Blue is a trademark of Hydrofera, LLC. ©2015 Hollister Incorporated.

# Gentian Violet and Methylene Blue Polyvinyl Alcohol Foam Antibacterial Dressing as a Viable Form of Autolytic Debridement in the Wound Bed

ANDREW JOSEPH APPLEWHITE, MD  
PHYSICIAN  
BAYLOR WOUND CENTER  
DALLAS, TEXAS

BROCK LIDEN, DPM  
STAFF, CIRCLEVILLE FOOT & ANKLE CENTER  
REYNOLDSBURG PODIATRY CENTER  
REYNOLDSBURG, OHIO

PAUL ATTAR, PhD, MBA  
PRESIDENT  
BRIDGE PTS  
SAN ANTONIO, TEXAS

QUYEN STEVENSON, ARNP, CWOCN  
WOUND AND OSTOMY NURSE PRACTITIONER  
VETERANS AFFAIRS PUGET SOUND HEALTHCARE SYSTEM  
SEATTLE, WASHINGTON

## ABSTRACT

The objective of this article is to describe the results of a comparative porcine study that evaluated the effectiveness of a gentian violet and methylene blue (GV/MB) polyvinyl alcohol (PVA) antibacterial foam dressing in debriding eschar. The authors performed an *in vivo*, preclinical study on eschar-covered porcine wounds. Two clinical case studies are also included. Test products, GV/MB antibacterial foam dressing, collagenase ointment, collagenase ointment plus GV/MB antibacterial foam dressing, medical-grade honey, and moist gauze dressing (control), were applied to porcine wounds using a split-back study design. The percent of eschar removal and wound closure were measured and recorded at time points up to 14 days. Statistically significant reduction in eschar was observed with GV/MB dressing and with GV/MB dressing with collagenase. By day 14, the wounds with GV/MB dressing alone and GV/MB dressing with collagenase had eschar covering less than 25% of the wound bed area compared with collagenase alone, medical grade honey, or moist gauze control, which showed eschar still covering over 75% of the wound bed area. Autolytic debridement activity of GV/MB foam dressings was evident in the porcine eschar study, as well as in the cases described.

## INTRODUCTION

The wound healing process is complex and can be prolonged with the presence of nonviable tissue in the wound bed. Debridement is an essential component of the wound healing process with multiple goals, including the removal of necrotic devitalized tissue, slough, senescent cells, and mechanical barriers.<sup>1</sup> In addition, debridement stimulates growth factor activity, reduces matrix metalloproteinases, and reinitiates the wound healing cascade.<sup>2,3</sup> There are five main methods of debridement: surgical or sharp, autolytic, enzymatic, mechanical, and biosurgery/maggots.<sup>4</sup> A detailed review of the advantages and disadvantages of each debridement method is beyond the scope of this paper; however, it is important for clinicians to have a working knowledge of the methods available to serve the well-being of each patient.<sup>5</sup>

The clinical decision regarding debridement methodology is based on multiple factors, including evidence of efficacy, pain tolerance of the patient, clinician skill level required to perform the procedure, products being utilized, and potential risks and side effects of the procedure. Sharp debridement is generally considered to be the quickest and most effective of the modalities; however, many patients are not candidates or do not consent to the procedure due to the pain. Chemical and autolytic agents are commonly used to facilitate debridement with or without sharp debridement.

Successful use of chemical agents and enzymatic ointments has been reported

in the debridement and treatment of infected wounds.<sup>1,6</sup> However, while the use of chemical debriding agents has grown in recent years, certain factors increasingly limit their use in clinical practice. For example, cost increases and reimbursement changes have severely reduced the amount of enzymatic debriding ointment allowed in numerous care settings, given the 2014 U.S. Hospital Outpatient Prospective Payment System.<sup>7</sup>

Autolytic debridement may be the safest form of wound debridement because it is highly selective in removing only devitalized tissue. The body's phagocytic cells and endogenous proteolytic enzymes are used to break down dead tissue, thus liquefying slough and necrotic tissue only. Autolytic debridement can be enhanced in conjunction with the use of occlusive and semi-occlusive dressings to maintain a moist environment.<sup>8</sup>

Preliminary evidence suggests a gentian violet and methylene blue (GV/MB) antibacterial foam dressing may be effective in promoting autolytic debridement in certain wounds.<sup>9</sup> GV/MB antibacterial dressings are sterile, absorptive foam dressings made by preferentially binding two antibacterial dyes, methylene blue and gentian violet, to open-celled polyvinyl alcohol (PVA) foam. The binding of the pigments to the foam helps prevent the pigments from washing away and becoming diluted. The GV/MB antibacterial dressing is cut to the desired size, then moistened with sterile saline or sterile water. Excess moisture is squeezed out, and the dressing is placed in the wound and secured with a secondary dressing to

prevent displacement and maintain moisture content. Dressings may be left in place for up to three days.

GV/MB antibacterial foam dressings are highly absorptive without risk of residual absorption.<sup>10,11</sup> Gentian violet and methylene blue pigments have historically shown broad spectrum activity against microorganisms commonly found in wounds and external surfaces of the skin. GV/MB foam dressings have been found *in vitro* not to exhibit any signs of cytotoxicity or systemic toxicity.<sup>11</sup> As such, the dressings can be used for extended periods and throughout all phases of wound healing. The purpose of this article is to describe the results of a comparative *in vivo*, preclinical porcine study that evaluated the effectiveness of a GV/MB PVA antibacterial foam dressing in debriding eschar, and to present clinical case studies that illustrate the clinical effects of the dressing on autolytic debridement.

## ANIMAL STUDY METHODS

An *in vivo* porcine model was utilized to evaluate the wound debridement activity of four test articles and controls: (1) a GV/MB antibacterial foam dressing, (2) a collagenase ointment, (3) collagenase ointment plus GV/MB antibacterial foam dressing, (4) medical-grade honey, and (5) moist dressing (control). Debridement performance was tested using a Yorkshire pig model, which has previously been recognized as an effective animal model for testing new debriders.<sup>12</sup> The animals were housed and cared for in accordance with the guidelines published by the National Research Council and approved by the Association for Assessment and Accreditation of Laboratory Animal Care.<sup>13</sup> Approval for this study was granted by the Bridge PTS Institutional Animal Care and Use Committee in San Antonio, Texas.

Three pigs were premedicated and anesthetized. Each pig was prepared for surgery by scrubbing with chlorohexidine and isopropyl alcohol in an alternating fashion three times to mimic the skin preparation in humans and the treatment site. In order to create an eschar suitable for a debridement study, a series of 20 eschar segments were created with a heated brass rod (10 on each side, 20 mm in diameter and 2 cm

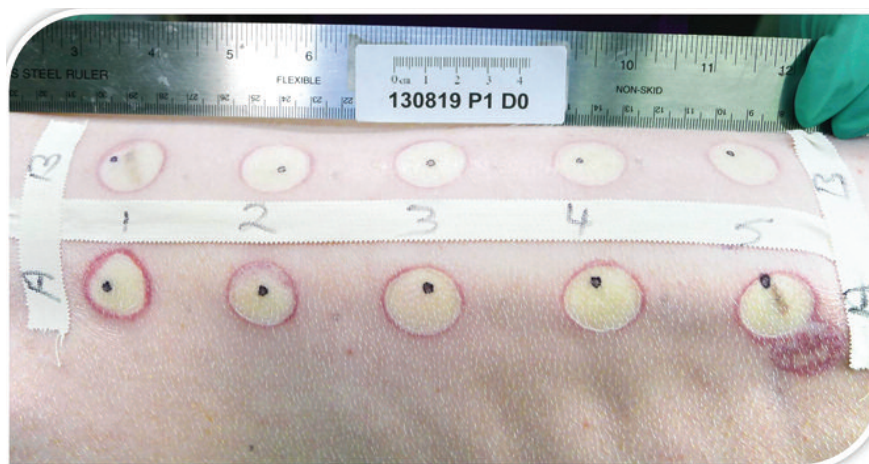


Figure 1. A series of eschar segments was created with a heated brass rod (10 on each side, 20 mm in diameter, and 2 cm apart).



**Table I**  
**Split-back study design protocol during porcine eschar wound study**

Porcine subject	Left side treatment	Right side treatment	Dressing change frequency
1	GV/MB moistened and covered with 4-layer gauze and taped	Moist dressing control	q 72 hours
2	Collagenase covered with dry gauze	Collagenase covered with moist GV/MB dressing	q 24 hours
3	Medical-grade honey covered with dry gauze	Moist dressing control	q 24 hours

apart) (Fig. 1). No surgical debridement occurred after the rods were applied, to permit eschar to develop from the devitalized tissue.

Test products were applied to the porcine eschar wounds using a split-back study design. For each of the three pigs, half of the wounds (n = 10) were treated with one dressing, and the other half were treated with a different dressing according to Table I. All products were applied and changed in accordance with their instructions for use.

The GV/MB foam dressing was moistened, excess moisture was wrung out, and the dressing was covered with 4-layer gauze, taped, and wrapped with an absorbent underpad. To ensure there was no mechanical debridement due to product dryness, the dressing was remoistened prior to removal. Collage-

nase was covered with gauze. In the case of collagenase combined with GV/MB foam, collagenase was covered with moistened and wrung-out GV/MB foam, then covered with dry gauze and wrapped with an absorbent underpad.

All the treated and control wounds (including those treated with GV/MB foam dressings) were covered with a transparent film dressing as the primary dressing and underpad as the secondary dressing. The occlusive layer of the blue underpad was placed against the skin. The pigs were wrapped with a layer of elastic bandage over the blue pad to prevent movement of the dressings underneath. If gauze became adherent to the wound bed during dressing changes, sterile saline was applied to help loosen it from the underlying tissue.

Visual assessment of the eschar was performed at each dressing change. For each wound, calipers were used to measure the distance across the widest part of the wound as well as the narrowest part of the wound. The estimated wound and eschar areas were calculated by using the equation for an ellipse (narrowest X widest X 3.14 / 4).

Presence of eschar was documented in the following manner:

- 1 = No evidence of eschar formation
- 2 = Eschar covering ≤25% of wound area
- 3 = Eschar covering 26% to 50% of wound area
- 4 = Eschar covering 51% to 75% of wound area
- 5 = Eschar covering 76% to ≤100% of wound area.

**Table II**  
**Presence of eschar**

Day	0	1	4	7	10	13	14	p-values
GV/MB foam dressing	5	5	5	4	4	3	2	<.01
Collagenase	5	5	5	5	4	4.5	5	0.49
Collagenase-GV/MB foam dressing	5	5	5	5	3	2	2	<.01
Medical grade honey	5	5	5	5	4	4	5	0.16
Moist gauze (control)	5	5	5	5	5	5	5	

- 1 = No evidence of eschar formation
- 2 = Eschar covering ≤25% of wound area
- 3 = Eschar covering 26% to 50% of wound area
- 4 = Eschar covering 51% to 75% of wound area
- 5 = Eschar covering 76% to ≤100% of wound area

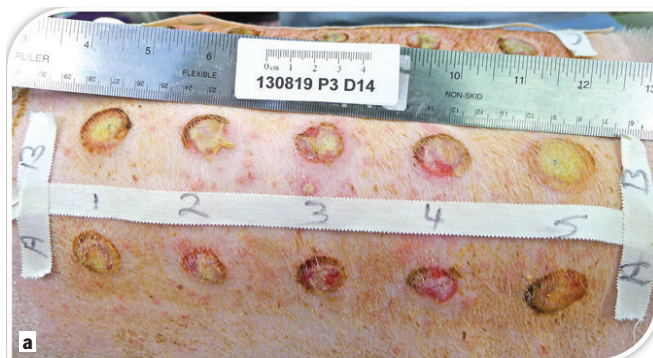

Figure 2a. Day 14 eschar that has been treated with honey. Eschar is still intact.

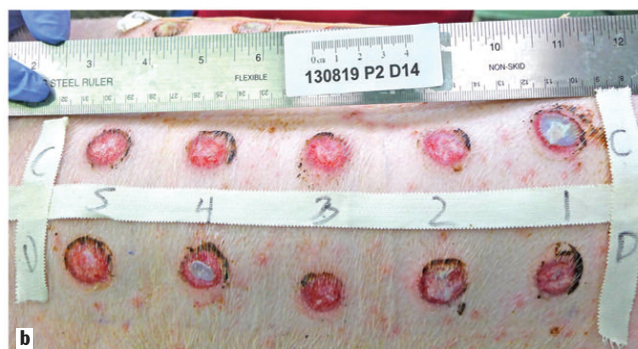


Figure 2b. Day 14 eschar that has been treated with GV/MB antibacterial dressing and collagenase. Eschar is almost completely debrided.

## RESULTS

Statistically significant reduction in eschar was seen with GV/MB dressing and with GV/MB dressing with collagenase (Table II). By day 14, the wounds with GV/MB dressing alone and GV/MB dressing with collagenase had eschar covering less than 25% of the wound bed area compared with all other products, which had eschar still covering over 75% of the wound bed area. Figures 2a and 2b show significantly reduced eschar with GV/MB antibacterial dressing versus honey on day 14. No statistically significant differences in wound size were seen at day 14. All of the products tested were similarly nonirritating and resulted in little or no swelling.

## HUMAN CASE STUDIES

The following clinical case studies in humans are examples of effective wound debridement demonstrated with use of the GV/MB antibacterial dress-

ing in chronic wounds. In all cases, the original goals for the dressing were to minimize potential recurrent bioburden and biofilm buildup, provide a less painful and easier removal of the dressing, and assist with absorption of exudate. In each of these cases, clinicians reported autolytic debridement of slough and necrotic tissue with use of the GV/MB antibacterial dressing.

### Clinical Case Study 1: Necrobiosis Lipoidica in a Nondiabetic Patient

A 34-year-old male presented with wounds that had spontaneously opened six years prior on his left lower extremity. The patient had no prior injuries or surgeries, but reported a history of chronic untreated edema and mild psoriasis in the lower extremities. The patient had received unknown treatment previously at an outpatient hospital-based clinic.

At the initial clinic visit, the wounds were washed with an antimicrobial soap (Fig. 3a). Skin biopsies and tests were negative for malignancy and underlying vascular or arterial disease. A pseudomonas infection was treated successfully, with some improvement in

wound healing. Throughout the course of the first week, the patient had a painful allergic reaction to all silver-based products, including silver alginate, foams, and creams.

The patient received 3 weeks of GV/MB antibacterial dressing treatments used in conjunction with compression bandages changed weekly in an outpatient wound clinic (Fig. 3b), per physician utilization and preference. The patient was treated as if he had chronic venous insufficiency and lower extremity edema, as all other possible etiologies were ruled out by original biopsy. The wound bed improved, appearing clean and beefy red. With weekly GV/MB antibacterial dressing changes and compression, the wound continued to improve, and at six months, the wound was closed. Following multiple additional tests and biopsies, the patient was being treated with oral steroids for necrobiosis lipoidica.

### Clinical Case Study 2: Nonhealing Venous Ulceration

A 66-year-old male presented to the wound clinic after failed treatment of multiple bilateral lower extremity

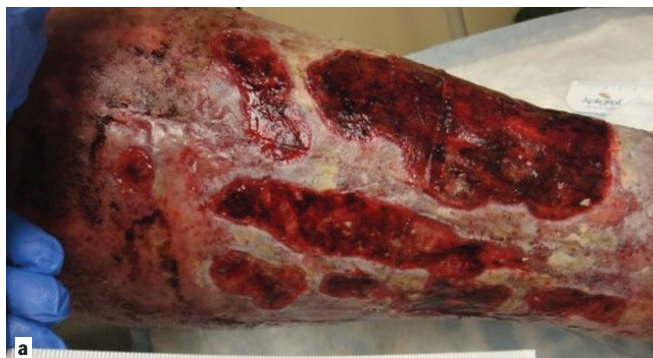

Figure 3a. At initial clinic visit after lower extremity chronic wounds were washed with an antimicrobial soap.

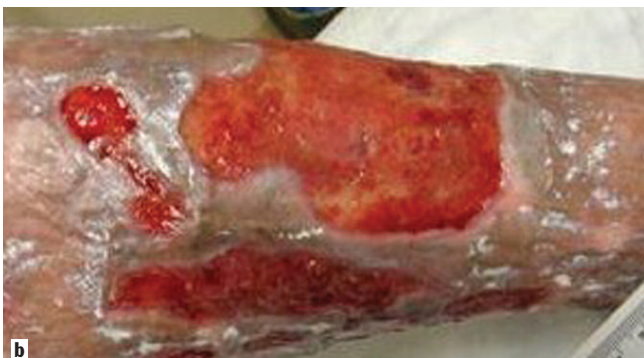

Figure 3b. Wounds after three weeks of GV/MB antibacterial dressing treatments used in conjunction with aggressive class II compression bandage systems.

ulcerations that had been present for 4 months following hospitalization for acute exacerbation of congestive heart failure (Figs. 4a & 4b). The patient's medical history included atrial fibrillation, Hodgkin's lymphoma, testicular cancer, stage III-IV chronic renal failure, hypothyroidism, new onset of uncontrolled type II diabetes mellitus, obstructive sleep apnea, and chronic obstructive pulmonary disease. Previous treatments included collagen with and without silver, silver and standard calcium alginate dressing, silver and standard foam dressings, collagenase debridement ointment, and silver gels and creams in combination with class II compression bandage systems.

The GV/MB antibacterial dressing was dampened with normal saline and applied bilaterally to all wounds, followed by abdominal pads, and class II compression bandage systems. Dressings were changed two times per week at an outpatient wound clinic. At two weeks, the wounds were smaller and beefy red, and did not require repeat debridement (Fig. 4c). After the patient had multiple recurrent hospitalizations for congestive heart failure exacerbation and kidney failure, the wounds continued to improve and eventually healed after 8 months of treatment with GV/MB dressings.

## DISCUSSION

Analysis of the visual clinical assessments in the porcine eschar model showed a significantly lower median score of eschar remaining in wounds treated with GV/MB foam as well as the combination of GV/MB foam and

collagenase, versus collagenase alone, medical-grade honey, or the moist gauze control. Autolytic debridement activity was evident in the porcine eschar study, as well as in the cases described. Similar rates of wound size reduction were reported with GV/MB foam versus the control on day 14. Meanwhile, significantly greater eschar reduction was observed with the GV/MB foam and collagenase-GV/MB foam combination versus the control on day 14. Wound size reduction occurred in control wounds despite the lack of debrided eschar. This difference suggests that reduction in eschar in the acute porcine wounds may not have been associated with wound size reduction.

The exact mechanisms of action leading to the observed faster rate of autolytic debridement and reduction of eschar are not fully understood, but several mechanisms have been proposed. One proposal is that because the hydrophilic, three-dimensional, open-cell structure of PVA foam is known to be highly absorptive with substantial retention and wicking,<sup>14</sup> the efficient management of excess exudate can enhance the natural process of autolytic debridement.<sup>15</sup> Contact of the moist dressing with the wound bed appeared to maintain a balanced, moist wound environment needed for autolytic debridement to occur. Shi and colleagues have previously confirmed compatibility of the GV/MB foam with enzymatic debriding ointments.<sup>16</sup> However, the similar rates of eschar and wound size reduction achieved with or without collagenase in the porcine study suggest that the addition of collagenase with GV/MB foam may not aid in overall debridement of acute wounds with eschar.

The antibacterial nature of the

GV/MB dressing may also contribute to autolytic debridement effects. Heavy bacterial burden in a wound leads to tissue degradation and slough formation. The two antibacterial organic pigments, methylene blue and gentian violet, are preferentially bonded to the PVA foam dressing. These pigments have been shown in previous studies to alter the redox environment to a state that is not conducive to bacterial growth or attachment.<sup>17,18</sup> Additionally, the pigments in the GV/MB dressing do not appear to inhibit fibroblast growth factor activity.<sup>19</sup> The GV/MB antibacterial foam dressing is indicated for pressure ulcers, diabetic ulcers, venous stasis ulcers, arterial ulcers, superficial burns, donor sites, postsurgical incisions, trauma wounds, abrasions, and lacerations.

Published research regarding the effects of GV/MB foam dressing in wound healing is limited. Because the dressing is classified as antibacterial, usage has naturally been concentrated on bioburden control in colonized wounds.<sup>9,20</sup> In a small series of 15 patients with lower extremity chronic wounds treated with GV/MB foam dressing, improvements in surface critical colonization and pain score at the end of the study period were noted in some patients, particularly in patients with diabetic foot ulcers. Decreased wound size was observed in 8 of 14 patients (57%) at week 4. The authors also observed autolytic debridement in some wounds, with the presence of slough on the surface of the removed dressing.<sup>9</sup>

The porcine eschar model study described herein is the first to show the comparative autolytic debridement effects of GV/MB antibacterial foam dressing. This debridement effect may

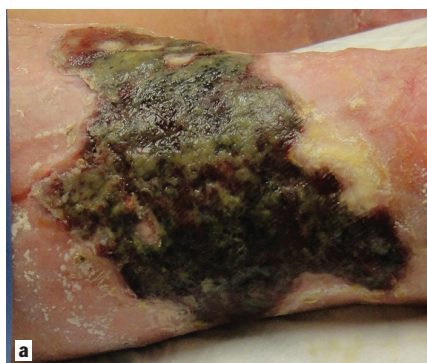


Figure 4a. Right venous leg ulcer at initial presentation.

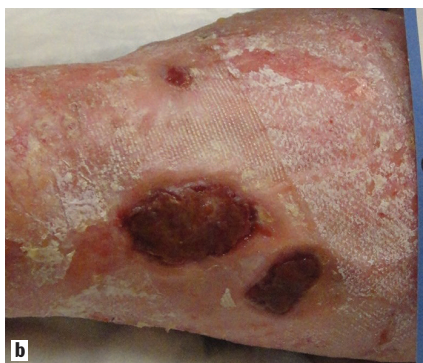

Figure 4b. Left venous leg ulcer at initial presentation.

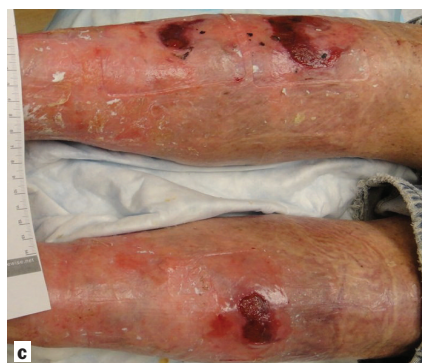

Figure 4c. Bilateral venous ulcers after two weeks of treatment with GV/MB antibacterial dressings and compression. Repeat debridement no longer required.



be of particular benefit in wounds that contain slough or eschar. However, larger-scale trials are needed to detect statistically significant differences in debridement effects of the GV/MB dressing in humans, and these results should be interpreted with caution.

Although thermal rods were used to create 3<sup>rd</sup>-degree burns in the porcine model, the primary purpose of the animal study was to test the effect of dressings in debriding eschar, rather than in treating thermal burn wounds. GV/MB foam dressings are not indicated for 3<sup>rd</sup>-degree burns in humans. The thermal burn method of eschar creation was chosen for this animal study based on the benefit of a consistent and readily controlled degree of tissue damage and eschar through a combination of weight, time, and temperature. Due to known differences in eschar reduction following thermal injury, these eschar reduction results may not be generalizable to greater wound populations.

## CONCLUSION

GV/MB antibacterial foam dressings appeared to be a safe, noncytotoxic method for managing porcine eschar wounds as well as chronic wound cases presented in this study. Use of GV/MB foam dressings as well as the combination of GV/MB foam and collagenase led to significantly greater eschar reduction in porcine wounds versus collagenase alone, medical-grade honey, or the moist gauze control. Although the GV/MB antibacterial foam dressing is not specifically indicated for debridement, the porcine and clinical results referenced in this manuscript suggest the dressing does aid in autolytic debridement. Additional research is warranted to further evaluate the stand-alone or adjunctive autolytic effects of GV/MB antibacterial foam dressings in clinical practice. **STI**

## AUTHORS' DISCLOSURES

Dr. Applewhite, a consultant for Hollister Wound Care, received payment for manuscript preparation. Dr. Attar, a consultant for Hollister Wound Care, received a corporate grant from Hollister to conduct the animal study reviewed in this manuscript. Dr. Liden, a consultant for Hollister Wound Care, received payment for manuscript preparation. Quyen Stevenson, a member of the Hollister Wound Care Speakers Bureau, received payment for manuscript preparation.

## REFERENCES

1. Shi L, Carson D. Collagenase santyl ointment: A selective agent for wound debridement. *J Wound Ostomy Continence Nurse* 2009;36(6S):S12–S16.
2. Falanga V, Harding KG (eds). *The clinical relevance of wound bed preparation*. New York: Springer Verlag, 2002.
3. Ayello E, Cuddigan J, Kerstein MD. Skip the knife: debriding wounds without surgery. *Nursing* 2002;32(9):58–63.
4. Broadus C. Wound care advisor. Debridement options: BEAMS made easy. March 25, 2013. Available at: [http://woundcareadvisor.com/debridement-options-beams-made-easy\\_vol2-no/](http://woundcareadvisor.com/debridement-options-beams-made-easy_vol2-no/). Accessed June 26, 2014.
5. Gywnne B, Newton M. An overview of the common methods of wound debridement. *British Jour Nursing* 2006;15(19):S4–S10.
6. Ramundo J, Gray M. Enzymatic wound debridement. *Jour Wound, Ostomy, and Continence Society* 2008;35(3):273–80.
7. Smith & Nephew, Inc. Navigating wound care reimbursement. 2014 coding and Medicare payment for application of collagenase Santyl<sup>®</sup> ointment. 2014. Available at: [http://www.santyl.com/content/pdf/2014\\_Santyl\\_Application\\_and\\_Coding\\_Payment\\_Sheet.pdf](http://www.santyl.com/content/pdf/2014_Santyl_Application_and_Coding_Payment_Sheet.pdf). Accessed on: November 1, 2014.
8. Vowden KR, Vowden P. Wound debridement, part 2: sharp techniques. *J Wound Care* 1999;8(6):291–94.
9. Coutts PM, Ryan J, Sibbald RG. Case series of lower-extremity chronic wounds managed with an antibacterial foam dressing

bound with gentian violet and methylene blue. *Adv Skin Wound Care* 2014;27(3 Suppl 1):9–13.

10. Woo KY, Alam T, Marin J. Topical antimicrobial toolkit for wound infection. *Surg Technol Int* 2014;25:45–52.

11. United States Food and Drug Administration. “Premarked Notification 510(K) Hydrofera LLC.” January 4, 2014. Available at: [http://www.accessdata.fda.gov/cdrh\\_docs/pdf13/K130670.pdf](http://www.accessdata.fda.gov/cdrh_docs/pdf13/K130670.pdf). Accessed January 12, 2015.

12. Shi L, Ermis R, Lam K, et al. Study on the debridement efficacy of formulated enzymatic wound debriding agents by in vitro assessment using artificial wound eschar and by an in vivo pig model. *Wound Repair Regen* 2009;17(6):853–62.

13. National Research Council. *Guide for the care and use of laboratory animals*, 8th Edition. The National Academies Press. 2013. Available at: <http://grants.nih.gov/grants/olaw/Guide-for-the-care-and-use-of-laboratory-animals.pdf>. Accessed on November 3, 2014.

14. Ovington LG. Dressings and skin substitutes. In: McCulloch JM, Kloth LC (eds). *Wound healing: evidence-based management*. 4th ed. Philadelphia: F.A. Davis Company; pp 231–47, 2010.

15. Romanelli M, Vowden K, Weir D. Exudate management made easy. *Wounds International* 2010;1(2):1–6.

16. Shi L, Ermis R, Kiedaisch B, et al. The effect of various wound dressings on the activity of debriding enzymes. *Adv Skin Wound Care* 2010;23(10):456–63.

17. Ingraham MA. The bacteriostatic action of gentian violet and its dependence on the oxidation-reduction potential. *J Bact* 1933;26:573–98.

18. Dubos R. The relation of the bacteriostatic action of certain dyes to oxidation-reduction processes. *J Exptl Med* 1929;49:575–92.

19. Ramsay S, Jelf C, Aust D, et al. Comparison of the effects of antimicrobial wound dressings on cell viability, proliferation, and growth factor activity. Poster presented at: World Union of Wound Healing Societies Congress, June 4–8, 2008, Toronto, Canada.

20. Sibbald RG, Ovington LG, Ayello EA, et al. Wound bed preparation 2014 update: management of critical colonization with a gentian violet and methylene blue absorbent antibacterial dressing and elevated levels of matrix metalloproteases with an ovine collagen extracellular matrix dressing. *Adv Skin Wound Care* 2014;27(3 Suppl 1):1–6.



Copyright © 2015 by  
Surgical Technology Online  
Tel. +1 415 704 3160

Email: [info@surgicaltechnology.com](mailto:info@surgicaltechnology.com), Internet: [www.surgicaltechnology.com](http://www.surgicaltechnology.com)